

THE EFFECT OF SIZE OF ND:YAG LASER POSTERIOR CAPSULOTOMY ON VISUAL ACUITY AND REFRACTION

Munavvar Ansari¹, Shakeer Pullambalavan²

¹Specialist, Department of Ophthalmology, Hamad Medical Corporation, Al Khor Hospital, Al Khor, Qatar.

²Associate Consultant, Department of Ophthalmology, Hamad Medical Corporation, Al Khor Hospital, Al Khor, Qatar.

Received : 06/04/2023
Received in revised form : 11/05/2023
Accepted : 24/05/2023

Keywords:

Posterior capsular opacification; capsulotomy; refraction; visual acuity, visual field, automated perimetry.

Corresponding Author:

Dr. Shakeer Pullambalavan,
Email: shakeerp@rediffmail.com

DOI: 10.47009/jamp.2023.5.3.195

Source of Support: Nil,
Conflict of Interest: None declared

Int J Acad Med Pharm
2023; 5 (3); 947-950



Abstract

Background: Purpose: To study the effect of size of Nd:YAG laser posterior capsulotomy on visual acuity & refraction. **Materials and Methods:** This prospective study was performed on 91 eyes of 78 patients who were diagnosed as posterior capsule opacification (PCO), following uncomplicated cataract surgery in a tertiary eye centre in North India. Patients were divided into two groups according to the size of capsulotomy. Groups comprised capsulotomy opening of less than or equal to 3 mm (Group 1) or greater (Group 2). All the patients were examined pre-procedure and 4 weeks after Nd:YAG capsulotomy. Visual acuity and refraction were done before performing the procedure and at subsequent visit. None of the patients received prophylactic anti-glaucoma medications either before or after the procedure. **Results:** There were 44 males and 34 female patients included in the study. Mean age of the patients was 55.87 ± 10.24 years (45-80 years). BCVA improved significantly following capsulotomy. There was no significant change in spherical equivalent (SE) compared to preoperative values in both the groups. There was no significant difference between the BCVA and mean deviation between the two groups before and after the capsulotomy. **Conclusion:** Capsulotomy with an opening of 3 mm or less is more beneficial in the improvement of visual function with very minimal complications.

INTRODUCTION

Cataract is the most common cause of blindness worldwide, and surgical removal is the most common method used to treat it.^[1] Cataract surgery has improved in recent years, but postoperative complications still occur with the most common complication being posterior capsular opacification (PCO). The usual visual complications secondary to posterior capsule opacification (PCO) are decreased visual acuity, impaired contrast sensitivity, glare disability, and monocular diplopia, which often requires further treatment.^[2,3]

Postoperative capsular opacification is mainly caused by migration and proliferation of residual lens epithelial cells (LECs) after cataract surgery and their differentiation into fibroblastic and lens fiber-like cells. It occurs more frequently and is more severe in young patients than in old, as they exhibit increased numbers of LECs and greater mitotic activity. Currently, the standard treatment for PCO is Nd:YAG laser posterior capsulotomy, which has a success rate of more than 95%.^[4] Laser capsulotomy uses a quick-pulsed Nd:YAG laser to

apply a series of focal ablations in the posterior capsule and create a small circular opening in the visual axis.^[5] Although safe and effective, the reported complications of Nd:YAG laser posterior capsulotomy include retinal detachment,^[6-8] cystoid macular edema (CME),^[6,9] and rise in IOP.^[10,11]

This procedure also causes a shift in the position of the implant.^[12,13] which can cause a change in the effective power of the lens in the eye and potentially alter the refraction of the patient. This might necessitate further refraction for the patient to ensure optimal vision. A number of Nd:YAG laser capsulotomy shapes and sizes may be utilized. Cruciate and circular shapes are most commonly performed with a wide range of opening sizes (3-6 mm). Specific capsulotomy shapes and sizes confer particular advantages and disadvantages.^[14,15] The influence that cataracts have on automated perimetry has been well studied.^[16-18] Concerning PCO however, some studies have been undertaken by analyzing its effects on visual acuity, contrast sensitivity, and glare, as well as on the improvement of these parameters after Nd: YAG capsulotomy.^[2-3,20-22] and also the influence of pseudophakia

without PCO on kinetic.^[23-26] or static perimetry.^[27,28]

In this study, we evaluated the effect of Nd:YAG capsulotomy size on visual outcomes and refraction of patients affected by PCO before and after Nd:YAG Capsulotomy.

MATERIALS AND METHODS

This study was performed according to the tenets of the Declaration of Helsinki and written informed consent was obtained from the patients before the intervention. The study was a prospective, descriptive study conducted in a tertiary eye centre in North India between Jan 2019 to Jan 2020. A total of 91 pseudophakic eyes of 78 patients with PCO with BCVA $\leq 6/12$ were included in the study. Only those cases that had undergone uncomplicated manual small incision cataract surgery or phacoemulsification with posterior chamber intraocular lens (PCIOL) in the bag implantation surgery were included in the study. The surgeries were performed by multiple surgeons. Exclusion criteria included complications during cataract surgery or during the postoperative period. The patients with following conditions were excluded from the study: Diagnosed cases of glaucoma or steroid responders, those with corneal opacities, retinal diseases, uveitis, optic neuropathy, and those who had undergone any other ophthalmic surgeries prior to Nd:YAG laser posterior Capsulotomy treatment.

All the patients underwent Nd:YAG laser Capsulotomy from January 1, 2019 to December 31, 2020. They were examined preoperatively and at 1 month after Nd:YAG laser capsulotomy. Patients were divided into two groups according to the size of the capsulotomy (Group 1 less than or equal to 3mm and Group 2 more than 3 mm). There were 50 eyes in Group 1 and 41 eyes in Group 2. Multiple surgeons performed the capsulotomy, though each capsulotomy was performed by a single surgeon in a single session with a Nd:YAG laser, Zeiss Visulas III laser (Carl Zeiss Meditec Inc, Dublin, California, USA). All patients underwent a complete ocular examination on all visits, including BCVA, refraction (autorefractometer followed by subjective refraction), slit lamp biomicroscopy, IOP measurement. The spherical equivalent (SE) values were calculated as the sum of the sphere plus half the cylindrical power.

During the next visit, which was scheduled 4 weeks after capsulotomy, an identical complete ophthalmic examination was performed.

Preoperative and postoperative SE and BCVA were compared within groups and between groups prior to and at 1 month following capsulotomy.

All statistical analyses were performed using commercially available statistical software (SPSS version 22, SPSS, Inc., Chicago, IL). Data were compared using the Chi-Square test, Wilcoxon

Signed Ranks test, Mann-Whitney U test, or Kruger Wallis test as appropriate. P values of less than 0.05 were considered statistically significant.

RESULTS

A total of 91 eyes of 78 patients were included in the study. There were 44 males (56%) and 34 female (44%) patients included in the study. Mean age of the patients was 55.87 ± 10.24 years (45-80 years). Forty-five patients had unilateral PCO (57.7%) and 23 patients had bilateral PCO (42.3%). The mean interval between surgery and Nd:YAG laser capsulotomy was 30.19 ± 8.08 months (12-40). No significant difference in the interval between surgery and Nd:YAG laser capsulotomy was observed between groups ($p=0.97$). No statistically significant differences in age or gender were observed between groups ($p=0.254$ and $p=0.49$, respectively).

The mean pre-procedural SE was -0.81 ± 0.76 diopter (0.00-2.00) in Group 1, -0.44 ± 0.31 diopter (0.00-1.00) in Group 2. The mean pre-procedural SE was significantly higher (more myopic) in Group 1 ($p=0.021$). The mean post-procedural SE was -0.92 ± 0.74 diopter (0.00).

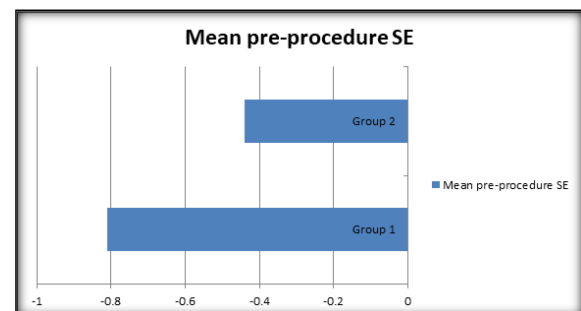


Figure 1: Mean pre-procedural SE

2.00) in Group 1, -0.26 ± 0.42 diopter (0.00-1.00) in Group 2. The mean post-procedural SE was significantly higher (more myopic) in Group 1 ($p=0.015$). No significant change in SE following capsulotomy was observed in any group ($p=0.081$).

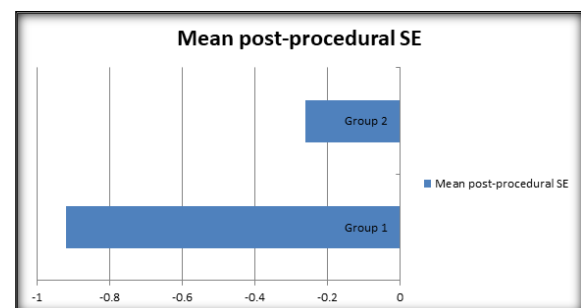


Figure 2: Mean post-procedural SE

The mean pre-procedural BCVA was 0.64 ± 0.32 logMAR units (0.20-0.90) in Group 1 and 0.68 ± 0.22 logMAR units (0.20-0.90) in Group 2. There was no statistical difference between groups ($p=0.54$). The mean post-procedural BCVA was

0.05 ± 0.07 logMAR units (0.00-0.20) in Group 1 and 0.06 ± 0.03 logMAR units (0.00-0.10) in Group 2. There was no statistical differences between groups (p=0.112). BCVA significantly improved in both groups following capsulotomy (P<0.01).

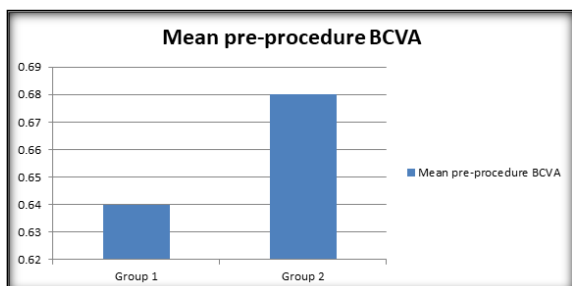


Figure 3: Mean pre-procedure BCVA

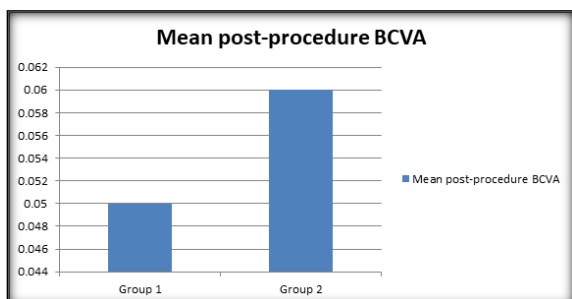


Figure 4: Mean post-procedure BCVA

No retinal complications (such as peripheral degenerations, retinal tears or retinal detachments) were found neither before nor after Nd: YAG was applied in both the groups.

DISCUSSION

The main goal of Nd:YAG laser capsulotomy is to increase visual acuity, however improving contrast sensitivity and decreasing disability due to glare are also important.^[20,29,30] Visual acuity through smaller capsulotomy openings is limited by diffraction and results in light passing through the unopened region of the capsule being scattered causing glare and decreasing contrast sensitivity. Capsulotomy opening should therefore be equal to, or larger than, the size of pupil in scotopic conditions.^[30,31] However, capsulotomy openings should be large enough to ensure good visualisation of the peripheral fundus, particularly in patients with retinal disease.

On the other hand, the complications associated with larger capsulotomy openings are increase risk of cystoid macular edema, vitreous prolapse, and retinal detachment.^[32,33] or posterior IOL dislocation leading to hyperopia.^[13] In addition, a higher amount of energy is required that may increase the risk of retinal detachment.^[34]

Refractive changes and visual acuity are usually not affected by the size and shape of capsulotomy.^[15,35,36] However, floaters are more frequently reported, and the amount of energy used

is higher, in circular shape and large size (>3mm) capsulotomies.^[15]

In our study we did not observe any complications related to Nd:YAG laser capsulotomy. Our study found no significant changes in refraction, visual acuity, or IOP in any groups following Nd:YAG capsulotomy. However, the amount of energy used, was significantly higher in Group 2 (large size circular shape capsulotomy). More energy and thus more laser firings are required to form larger capsulotomies resulting in more floating bodies in the anterior vitreous. Additionally, the amount of energy used and floater complaints were significantly lower in Group 1 (small size capsulotomy).

CONCLUSION

In conclusion, capsulotomy with an opening of 3 mm or less provides the greatest improvement in visual function with minimal complications.

REFERENCES

1. Lee, C.M.; Afshari, N.A. The global state of cataract blindness. *Curr. Opin. Ophthalmol.* 2017, 28, 98–103.
2. Claesson M, Klarén L, Beckman C, Sjöstrand J. Glare and contrast sensitivity before and after Nd: YAG laser capsulotomy. *Acta Ophthalmol (Copenh).* 1994; 72(1):27–32.
3. Sunderraj P, Villada JR, Joyce PW, Watson A. Glare testing in pseudophakes with posterior capsule opacification. *Eye.* 1992; 6(4):411. doi:10.1038/eye.1992.85
4. Pandey SK, Apple DJ, Werner L, Maloof AJ, Milverton EJ. Posterior capsule opacification: a review of the aetiopathogenesis, experimental and clinical studies and factors for prevention. *Indian J Ophthalmol.* 2004; 52 (2):99–112.
5. Aron-Rosa D, Aron JJ, Griesemann M, Thyzel R. Use of the neodymium-YAG laser to open the posterior capsule after lens implant surgery: a preliminary report. *J Am Intraocul Implant Soc.* 1980; 6(4):352–354.
6. Steinert RF, Puliafito CA, Kumar SR, Dudak SD, Patel S. Cystoid macular edema, retinal detachment, and glaucoma after Nd: YAG laser posterior capsulotomy. *Am J Ophthalmol.* 1991;112 (4):373–380.
7. Leff SR, Welch JC, Tasman W. Rhegmatogenous retinal detachment after YAG laser posterior capsulotomy. *Ophthalmology.* 1987;94 (10):1222–1225.
8. Javitt JC, Tielsch JM, Canner JK, Kolb MM, Sommer A, Steinberg EP. National outcomes of cataract extraction. Increased risk of retinal complications associated with Nd: YAG laser capsulotomy. The Cataract Patient Outcomes Research Team. *Ophthalmology.* 1992;99(10):1487–1497; discussion 1497–1488
9. Shah GR, Gills JP, Durham DG, Ausmus WH. Three thousand YAG lasers in posterior capsulotomies: an analysis of complications and comparison to polishing and surgical dissection. *Ophthalmic Surg.* 1986;17(8):473–477.
10. Channell MM, Beckman H. Intraocular pressure changes after neodymium-YAG laser posterior capsulotomy. *Arch Ophthalmol (Chicago, Ill: 1960).* 1984; 102(7):1024–1026.
11. Stark WJ, Worthen D, Holladay JT, and Murray G. Neodymium: YAG lasers: an FDA report. *Ophthalmology.* 1985; 92(2):209–212.
12. Thornval P, Naeser K. Refraction and anterior chamber depth before and after neodymium: YAG laser treatment for posterior capsule opacification in pseudophakic eyes: a prospective study. *J Cataract Refract Surg.* 1995; 21(4):457–460. doi:10.1016/S0886-3350(13)80540-8

13. Findl O, Drexler W, Menapace R, et al. Changes in intraocular lens position after neodymium: YAG capsulotomy. *J Cataract Refract Surg.* 1999; 25(5):659–662. doi:10.1016/S0886-3350(99) 00010-3
14. Yilmaz S, Ozdil MA, Bozkir N, Maden A. The effect of Nd:YAG laser capsulotomy size on refraction and visual acuity. *J Refract Surg.* 2006; 22(7):719-21.
15. Kara N, Evcimen Y, Kirik F, Agachan A, Yigit FU. Comparison of two laser capsulotomy techniques: cruciate versus circular. *Sem Ophthalmol.* 2014; 29(3):151-5.
16. Lam BL, Alward WL, Kolder HE. Effect of cataract on automated perimetry. *Ophthalmology* 1991; 98: 1066–1070.
17. Smith SD, Katz J, Quigley HA. Effect of cataract extraction on the results of automated perimetry in glaucoma. *Arch Ophthalmol* 1997; 115: 1515–1519.
18. Kim YY, Kim JS, Shin DH, Kim C, Jung HR. Effect of cataract extraction on blue-on-yellow visual field. *Am J Ophthalmol* 2001; 132: 217–220.
19. Wilkins M, McPherson R, Fergusson V. Visual recovery under glare conditions following laser capsulotomy. *Eye* 1996; 10: 117–120.
20. Magno BV, Datiles MB, Lasa MS, Fajardo MR, Caruso RC, Kaiser-Kupfer MI. Evaluation of visual function following neodymium :YAG laser posterior capsulotomy. *Ophthalmology* 1997; 104: 1287–1293.
21. Aslam TM, Aspinall P, Dhillon B. Posterior capsule morphology determinants of visual function. *Graefes Arch Clin Exp Ophthalmol* 2003; 241: 208–212.
22. Meur G. [Peripheral visual acuity in aphakia and pseudophakia]. *Bull Soc Belge Ophtalmol* 1983; 204–205: 55–60.
23. Flament J, Landre JC, Langer I, Piat JC. [The visual field of pseudophakic patients. Perimetric and statistical study]. *J Fr Ophtalmol* 1987; 10: 295–300.
24. Lazarus L, Williams TD. Visual field area in phakic, aphakic, and pseudophakic individuals. *Am J Optom Physiol* 1988; 65: 593–597.
25. Williams TD. Visual fields, acuity, and intraocular pressure in a pseudophakic patient. *Optom Vis Sci.* 1989; 66: 884–889.
26. Klewin KM, Radius RL, Schultz RO. Visual-field function in pseudophakia. *Ann Ophthalmol* 1988; 20: 316–317.
27. Nacef L, Jeddi A, Marrakchi S, Allagui M, Ayed S. [The visual field of patients with pseudophakia using kinetic and automated perimetry]. *J Fr Ophtalmol* 1992; 15: 405–409.
28. Hayashi H, Nakao F, Hayashi H. Influence of size of Nd:YAG laser posterior Capsulotomy on visual function. *Eye (Lond).* 2010;24(1):101-6.
29. Holladay JT, Bishop JE, Lewis JW. The optimal size of a posterior capsulotomy. *J Am Intraocul Implant Soc J.* 1985;11(1):18-20.
30. Nadler DJ, Jaffe NS, Clayman HM, Jaffe MS, Luscombe SM. Glare disability in eyes with intraocular lenses. *Am J Ophthalmol.* 1984;97(1):43-7.
31. Patton N, Aslam TM, Bennett HG, Dhillon B. Does a small central Nd:YAG posterior capsulotomy improve peripheral fundal visualisation for the vitreoretinal surgeon? *BMC Ophthalmol.* 2004; 4:8.
32. Ranta P, Tommila P, Kivela T. Retinal breaks and detachment after neodymium: YAG laser posterior capsulotomy: five years incidence in a prospective cohort. *J Cataract Refract Surg.* 2004;30(1):65-73. Comment in: *J Cataract Refract Surg.* 2005;31(8):1480.
33. Charles S. Vitreoretinal complications of YAG laser capsulotomy. *Ophthalmol Clin North Am.* 2001;14(4):705-10.
34. Chua CN, Gibson A, Kazakos DC. Refractive changes following Nd:YAG capsulotomy. *Eye (Lon).* 2001;15(Pt 3):304-5.
35. Yilmaz S, Ozdil MA, Bozkir N, Maden A. The effect of Nd:YAG laser capsulotomy size on refraction and visual acuity. *J Refract Surg.* 2006;22(7):719-21.